Advances in Peritoneal Dialysis, Vol. 24, 2008

Tumoral Calcinosis Without Hyperparathyroidism in a Patient on Continuous Ambulatory Peritoneal Dialysis

Arvin Gupta,[1] Yijuan Sun,[1] Konstantin N. Konstantinov,[2] Karen S. Servilla,[1] Michael F. Hartshorne,[3] Antonios H. Tzamaloukas[1]

Reports of tumoral calcinosis (TC) in peritoneal dialysis (PD) patients are rare. Reported PD patients with TC also had hyperparathyroidism. A 67-year-old man on continuous ambulatory PD for almost 3 years developed TC of the right wrist and knee and both shoulders and feet. In the 2 years preceding the diagnosis of TC, this patient's serum parathyroid hormone levels were consistently low (17 ± 12 pg/mL). Hypercalcemia had been found in 32% of the serum samples, hyperphosphatemia in 91%, and elevated Ca× P product in 78% of the samples. At presentation with TC, serum C-reactive protein was elevated, and serum levels of vitamin D compounds were below normal. Four months after the diagnosis of TC, the patient died with a combination of gastrointestinal and retroperitoneal bleeding episodes and septic events. Tumoral calcinosis may develop in PD patients without hyperparathyroidism. Sustained hyperphosphatemia and high Ca × P product are important in the pathogenesis of uremic TC. Elevated indices of inflammation may accompany TC. Studies are needed to identify other important factors in the pathogenesis of TC in PD patients and to evaluate treatment methods.

Key words
Tumoral calcinosis, hyperphosphatemia, hypercalcemia, hyperparathyroidism, inflammation

Introduction

In patients on chronic dialysis, ectopic calcifications cause morbidity and, almost certainly, mortality. Arterial calcifications, the commonest ectopic calcifications, are linked to morbid vascular events. Calciphylaxis is also recognized with increasing frequency and has a high mortality. Tumoral calcinosis (TC) is relatively uncommon and has been studied less intensively than have the other two conditions, but TC can cause discomfort and immobility. In hemodialysis patients, TC was initially described as a complication of hyperparathyroidism (1), but was subsequently found in patients with adynamic bone disease (2) or aluminum osteodystrophy (3). The few cases of TC reported in peritoneal dialysis (PD) patients were associated with hyperparathyroidism (4,5).

Here, we describe the development of TC in a patient on continuous ambulatory PD (CAPD). Hyperparathyroidism was absent, but hyperphosphatemia and elevated Ca × P product were sustained. Pathogenetic mechanisms and treatment of TC are discussed.

Case report

A 64-year-old man with end-stage renal disease secondary to diabetic nephropathy commenced CAPD with 4 daily exchanges, a 2-L fill volume, and 1.5% alternating with 2.5% dextrose content in November 2004. Peritoneal equilibration test revealed low-average transport. Urine flow rate exceeded 1 L in 24 hours and total (peritoneal plus renal) weekly Kt/V urea was consistently above 2.0 throughout the CAPD period.

This patient had an early exit-site infection with methicillin-sensitive *Staphylococcus aureus.* In September 2005, he was hospitalized twice, once for severe hyperglycemia and once for accidental severing of the PD catheter without peritonitis. Following these admissions, he had several lower gastrointestinal (GI) bleeding episodes requiring transfusions of red blood cells and intravenous iron infusions. Colonoscopies revealed adenomatous polyps and bleeding internal hemorrhoids.

From: [1]Section of Nephrology and [2]Section of Rheumatology, Medicine Service, and [3]Radiology Service, New Mexico VA Health Care System and University of New Mexico School of Medicine, Albuquerque, New Mexico, U.S.A.

In September 2007, the patient complained of a painless nodule in the extensor surface of the right wrist, stiffness and pain of the right knee, and pains in both feet causing a wheelchair existence. Radiographs and bone scan revealed extensive arterial calcifications and TC in the right wrist and knee, left elbow, both plantar areas, and both shoulders (Figures 1 and 2). The patient had not taken any vitamin D preparations. Calcium acetate, 667 mg with each meal was prescribed as the phosphate binder between December 2004 and February 2007, when sevelamer was substituted for calcium acetate because of hypercalcemia. He also consumed large amounts of calcium carbonate (Tums: GlaxoSmithKline, Philadelphia, PA, U.S.A.) for epigastric distress after September 2005, as was later discovered.

All oral calcium preparations were discontinued after the diagnosis of TC. Treatment with bisphosphonates was planned, but in rapid succession, he developed a duodenal ulcer, with severe upper GI bleeding requiring several transfusions of packed red blood cells; a cerebrovascular accident with right hemiplegia; *Klebsiella* pneumonia with bacteremia, endocarditis, and peritonitis necessitating transfer to hemodialysis; and a large spontaneous retroperitoneal hematoma. He died in January 2008 subsequent to intractable hypotensive shock.

Changes in the patient's laboratory values related to the development of ectopic calcifications occurred between the CAPD period before the two admissions in 2005 and the 2-year period preceding the diagnosis of TC. Table I shows these laboratory values in the pre-dialysis period (November 2000 – October 2004), in the CAPD period between November 2004 and September 2005 (period A), in the CAPD period between October 2005 and September 2007 (period B), and in the CAPD period between October 2007 and January 2008 (period C). Periods A and B were compared statistically. Calcium, phosphorus, Ca × P product, parathyroid hormone, glucose, and hemoglobin were higher in period A. Serum albumin and total CO_2 (tCO_2) were similar in periods A and B.

Hypercalcemia (>10.2 mg/dL), not found in periods A and C, was found in 7 samples (32%) in period B. Hyperphosphatemia (>5.0 mg/dL) was found in 5 samples (36%) in period A, 20 samples (91%) in period B, and 9 samples (36%), all during episodes of sepsis, in period C. Elevated Ca × P product (>55) was found

FIGURE 1 (A) Total body bone scan and plain radiography of the right upper extremity showing tumoral calcinosis (arrows). The radiographic image also shows extensive arterial calcification.

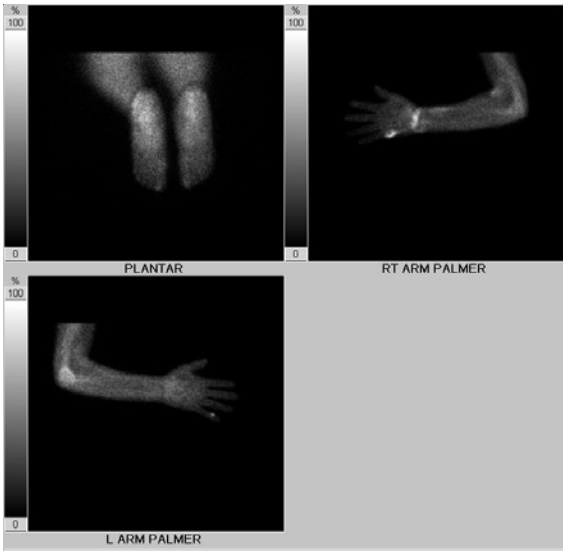

FIGURE 2 Details of the bone scan, further illustrating areas of tumoral calcinosis.

in 5 samples (36%) in period A, 16 samples (78%) in period B, and 5 samples (20%) in period C. Values of blood glycosylated hemoglobin and serum lipids, which were measured only once in period A, were numerically lower in period B than in period A. At presentation with TC, serum C-reactive protein (CRP) was 58.5 mg/L (normal range: <10 mg/L), serum 1,25-dihydroxycholecalciferol was 5.5 pg/mL (normal range: 25.1 – 66.1 pg/mL), and serum 25-hydroxycholecalciferol was 9.4 ng/mL (normal range: 20.0 – 100.0 ng/mL).

Discussion and conclusions

The main points of this case report are that

- hyperparathyroidism was not necessary for the development of TC, and
- sustained elevation both of serum phosphorus and of Ca × P product preceded development of TC.

The development of arterial calcifications depends to some extent on the same factors, but with significant differences. Arterial calcifications are also frequent in diabetic patients without renal failure or Ca × P product abnormalities. In patients on PD, such calcifications do not respond to treatments that otherwise have some effect on TC, including reduction of Ca × P product, parathyroidectomy, or agents solubilizing the calcium salts from the ectopic calcifications (6).

Although the idea that ectopic calcifications result from an elevation of Ca × P product above a threshold value represents an oversimplification (7), the fundamental biochemical abnormality leading to TC in

TABLE I Laboratory values[a] in serum and blood

Variable	*Pre-dialysis*[b]	*Period A*[b]	*Period B*[b]	*Period C*[b]
Calcium (mg/dL)	8.5±0.9 (9)	8.3±0.8 (16)	9.3±1.1[c] (26)	7.4±0.8 (25)
Phosphorus (mg/dL)	5.6±0.9 (9)	4.5±1.5 (14)	6.7±1.7[d] (22)	6.4±2.6 (25)
Ca × P	48±9 (9)	38±15 (14)	62±15[d] (22)	48±20 (25)
Albumin (g/dL)	3.7±0.4 (8)	3.0±0.4 (13)	2.8±0.3[e] (25)	2.3±0.3 (16)
iPTH (g/mL)	87±29 (3)	82±68 (6)	17±12[c] (7)	141±12 (4)
tCO_2 (mmol/L)	21.1±1.8 (10)	27.4±3.1 (19)	26.5±2.2[e] (26)	24.4±5.2 (42)
Glucose (mg/dL)	162±75 (10)	259±152 (22)	156±49[d] (30)	139±78 (42)
HbA1c (%)	7.5±1.3 (5)	16.0 (1)	6.6±0.2 (4)	5.8±0.8 (2)
Cholesterol (mg/dL)	256±21 (3)	202 (1)	143±18 (3)	174 (1)
HDL (mg/dL)	39±6 (2)	32 (1)	50±10 (2)	53 (1)
LDL (mg/dL)	158±15 (3)	106 (1)	64±17 (2)	94 (1)
Triglycerides (mg/dL)	262±26 (3)	253 (1)	146±55 (3)	131 (1)
Hemoglobin (g/dL)	11.6 (9)	12.7±1.2 (14)	9.9±2.8[c] (29)	9.7±2.2 —

[a] Mean ± standard deviation (samples studied).
[b] Pre-dialysis: November 2000 – October 2004; period A: November 2004 – September 2005; period B: October 2005 – September 2007; period C: October 2007 – January 2008.
[c] $p < 0.05$ as compared with period A. Comparisons used the Student two-tailed non-paired *t*-test.
[d] $p < 0.001$ as compared with period A.
[e] Nonsignificant as compared with period A.
PTH = intact parathyroid hormone (normal range: 11 – 67 pg/mL); tCO_2 = total carbon dioxide; HDL = high-density lipoprotein; LDL = low-density lipoprotein.

dialysis patients is thought to be an elevated Ca × P product (3). Sustained elevation of Ca × P was noted in the 2 years preceding the diagnosis of TC in the patient reported here (Table I). However, only a fraction of the patients with similar elevations in Ca × P develop TC (8). This suggests that other influences, in addition to an elevated Ca × P, have critical roles in the pathogenesis of TC (9). Administration of vitamin D derivatives leads to ectopic calcifications in uremic animals (10). Associations between TC and intake (11) or aberrant metabolism (12) of vitamin D have been reported. However, our patient never took vitamin D preparations. Vitamin D levels in his serum were below normal when TC was diagnosed.

The association between chronic inflammation, which reduces the levels of endogenous inhibitors of calcification in body fluids, and arterial calcifications (13) or calciphylaxis (14) has been recognized. Induction of inflammation by TC has been reported (15,16). Serum CRP was elevated in the patient reported here when TC was diagnosed. However, whether inflammation can lead to the development of TC is not currently known.

Hyperlipidemia and diabetes have been associated with arterial calcifications. Metabolic acidosis has a protective effect on ectopic calcifications in uremic animals (17). The association of these three factors with TC has not been studied. In our patient, control of both serum glucose and lipids improved in the 2 years preceding the development of TC as compared with the first 10 months of CAPD, but serum tCO_2 was consistently on the high side (Table I).

Finally, mutations in several genes have been reported in familial TC (18,19), which has variants with and without hyperphosphatemia (20). The pathogenesis of uremic TC may be further elucidated by studies of the effects of uremia on these genes and on the metabolism of their products.

Decreases in the Ca × P product, parathyroidectomy, sodium thiosulfate (6) [which can be administered intraperitoneally in PD patients (21)], calcimimetics and bisphosphonates (16,22) have all been used in the treatment of TC. The characteristics of removal of certain bisphosphonates by hemodialysis have been studied (23). Studies of their removal by PD are needed.

References

1 Ibels LS. The pathogenesis of metastatic calcification in uraemia. Prog Biochem Pharmacol 1980;17:242–50.

2 Eisenberg B, Tzamaloukas AH, Hartshorne MF, Listrom MB, Arrington ER, Sherrard DJ. Periarticular tumoral calcinosis and hypercalcemia in a hemodialysis patient without hyperparathyroidism: a case report. J Nucl Med 1990;31:1099–103.

3 Zins B, Zingraff J, Basile C, *et al.* Tumoral calcification in hemodialysis patients: possible role of aluminum intoxication. Nephron 1992;60:260–7.

4 Kleinpeter MA. Spectrum of complications related to secondary hyperparathyroidism in a peritoneal dialysis patient. Adv Perit Dial 2000;16:286–90.

5 Raju DL, Podymow T, Barré P. Tumoral calcinosis in a peritoneal dialysis patient. Kidney Int 2006;70:1887.

6 Yatzidis H, Agroyannis B. Sodium thiosulfate treatment of soft-tissue calcifications in patients with end-stage renal disease. Perit Dial Bull 1987;7:250–2.

7 O'Neill WC. The fallacy of the calcium–phosphorus product. Kidney Int 2007;72:792–6.

8 De Francisco AM, Ellis HA, Owen JP, *et al.* Parathyroidectomy in chronic renal failure. Q J Med 1985;55:289–315.

9 Tzamaloukas AH, Murphy G, Eisenberg B. Extraosseous calcifications in patients on chronic dialysis. Int J Artif Organs 1994;17:311–14.

10 Lopez I, Mendoza FJ, Aguilera–Tejero E, *et al.* The effect of calcitriol, paricalcitol, and a calcimimetic on extraosseous calcifications in uremic rats. Kidney Int 2008;73:300–7.

11 Walker GS, Davison AM, Peacock M, McLachlan MS. Tumoral calcinosis: a manifestation of extreme metastatic calcification occurring with 1, α-hydroxycalciferol therapy. Postgrad Med J 1977;53:570–3.

12 Quarles LD, Murphy G, Econs MJ, Martinez S, Lobaugh B, Lyles KW. Uremic tumoral calcinosis: preliminary observations suggesting an association with aberrant vitamin D homeostasis. Am J Kidney Dis 1991;28:706–10.

13 Ketteler M, Wanner C, Metzger T, *et al.* Deficiencies of calcium-regulatory proteins in dialysis patients: a novel concept of cardiovascular calcification in uremia. Kidney Int 2003;63(suppl 84):S84–7.

14 Slough S, Servilla KS, Harford AM, Konstantinov KN, Harris A, Tzamaloukas AH. Association between calciphylaxis and inflammation in two patients on chronic dialysis. Adv Perit Dial 2006;22:171–4.

15 Christidou F, Bamichas G, Stangou M, Natse T, Kalpakidis V, Sombolos K. Tumoral calcinosis inducing systemic inflammatory response in a hemodialysis patient. Nephron 2002;92:497–8.

16 Phanish MK, Kallarackal G, Ravanan R, Lawson TM, Baboolal K. Tumoral calcinosis associated with pyr-

exia and systemic inflammatory response in a haemodialysis patient: successful treatment using intravenous pamidronate. Nephrol Dial Transplant 2000;15:1691–3.
17 Mendoza FJ, Lopez I, Montes de Oca A, Perez J, Rodriguez M, Aguilera–Tejero E. Metabolic acidosis inhibits soft tissue calcification in uremic rats. Kidney Int 2008;73:407–14.
18 Imel EA, Econs MJ. Fibroblast growth factor 23: roles in health and disease. J Am Soc Nephrol 2005;16:2565–75.
19 Sprecher E. Tumoral calcinosis: new insights for the rheumatologist into a familial crystal deposition disease. Curr Rheumatol Rep 2007;9:237–42.
20 Olsen KM, Chew FS. Tumoral calcinosis: pearls, polemics and alternative possibilities. Radiographics 2006;26:871–85.
21 Mataic D, Bastani B. Intraperitoneal sodium thiosulfate for the treatment of calciphylaxis. Ren Fail 2006;28:361–3.
22 Mori H, Okada Y, Tanaka Y. Etidronate for the treatment of progressive tumoral calcinosis in hemodialysis patients. Intern Med 2007;46:1485–6.
23 Buttazzoni M, Rosa Diez GJ, Jager V, Crucelegui MS, Algranati SL, Plantalech L. Elimination and clearance of pamidronate by haemodialysis. Nephrology (Carlton) 2006;11:197–200.

Corresponding author:
Antonios H. Tzamaloukas, MD, Renal Section (111C), New Mexico VA Health Care System, 1501 San Pedro SE, Albuquerque, New Mexico 87108 U.S.A.
E-mail:
Antonios.Tzamaloukas@med.va.gov