Rosiglitazone, a Peroxisome Proliferator–Activated Receptor Agonist, Improves Peritoneal Alterations Resulting from an Encapsulated Peritoneal Sclerosis Model

Devrim Bozkurt,[1] Hüseyin Taskin,[1] Murat Sezak,[2] Selahattin Biçak,[1] Sait Sen,[2] Ercan Ok,[1] Soner Duman[1]

Inflammation, fibrosis, and angiogenesis underlie the pathophysiology of encapsulating peritoneal sclerosis (EPS). The irreversible sclerosis of visceral and parietal peritoneum that characterizes EPS can be seen in peritoneal dialysis (PD) patients after long periods on dialysis.

Peroxisome proliferator–activated receptors (PPARs) are the major regulator of key metabolic pathways of various inflammatory responses in fibrosing processes in most tissues. The aim of the present study was to investigate the effect of the PPAR agonist rosiglitazone on the progression and regression of peritoneal alterations in chlorhexidine gluconate–induced EPS in rats.

We divided 53 nonuremic Wistar albino rats into 5 groups: control group—isotonic saline 2 mL, injected intraperitoneally (IP) daily for 3 weeks; chlorhexidine gluconate (CG) group—CG 2 mL per 200 g body weight, injected IP daily for 3 weeks; Rozi-P group—CG injection as described, plus rosiglitazone in drinking water (8 mg/L) for 3 weeks; resting group—CG injection as described during weeks 1 – 3, then peritoneal rest during weeks 4 – 6; Rozi-R group—CG injection as described during weeks 1 – 3, then rosiglitazone in drinking water (8 mg/L) during weeks 4 – 6. At the end of the study, a 1-hour peritoneal equilibration test (PET) was performed with 25 mL 3.86% glucose PD solution. Dialysate-to-plasma ratio of urea (D/P urea), dialysate white blood cell (WBC) count, ultrafiltration (UF) volume, and morphology change in parietal peritoneum were examined.

Exposure to CG for 3 weeks resulted in alterations in peritoneal transport (increased D/P urea, decreased UF volume, both $p < 0.05$*) and morphology (increased inflammation, neovascularization, fibrosis, and peritoneal thickness, all* $p < 0.05$*). Peritoneal rest had some advantages in UF failure and WBC count only (both* $p < 0.05$*). However, rosiglitazone was more effective than peritoneal rest for vascularity and peritoneal thickness (*$p < 0.05$*).*

We suggest that the PPAR agonist rosiglitazone may have a therapeutic value in the management of EPS by inhibiting inflammation and neovascularization.

Key words

Sclerosing encapsulating peritonitis, PPAR agonist, rat model

From: Departments of [1]Nephrology and [2]Pathology, Ege University, Izmir, Turkey.

Introduction

Inadequate solute clearance and ultrafiltration (UF) failure are the major long-term complications of patients on peritoneal dialysis (PD). Continuous exposure to bioincompatible and hypertonic dialysate solutions coupled with episodes of peritonitis, which together lead to sclerosis of visceral and parietal peritoneum, are the major factors contributing to development of UF failure. Encapsulating peritoneal sclerosis (EPS), characterized by a thickening of the peritoneum and formation of fibrous bands that enclose intestinal loops, is rare, but carries a high mortality rate. Its incidence increases with duration of PD treatment (1,2).

To achieve adequate solute clearance and UF in anuric patients, conventional peritoneal solutions with a high glucose concentration are commonly prescribed. These dialysis fluids with an acidic pH, lactate buffer, and high concentration of glucose are bioincompatible solutions that cause peritoneal fibrotic change. Most *in vivo* studies have demonstrated a strong correlation between glucose exposure and the production of transforming growth factor β-1 (TGFβ1) by mesothelial cells. Glucose also increases expression of vascular endothelial growth factor messenger RNA (mRNA), which results in neovascularization and UF failure. Most studies have shown that expression of the main fibrogenic factor TGFβ1 occurs chiefly as a result of two powerful stimuli: angiotensin II and hyperglycemia. Although structural disassembly of extracellular matrix components is a commonly shared features of almost all fibrotic processes, with the same mediators involved in all organs in which fibrogenesis takes place, no consensus has yet been reached concerning the management of peritoneal fibrosis in continuous ambulatory PD (CAPD) patients.

Peroxisome proliferator–activated receptors (PPARs) work as transcriptional factors for specific target genes that, in most tissues, are the regulators of key metabolic pathways including fatty acid oxidation, adipocyte differentiation, insulin sensitivity, and inflammatory responses of various kinds in the milieu of metabolic syndrome complex. Several experimental models show that either endogenous or exogenous ligands that activate these three isoforms possess multiple anti-inflammatory properties.

Various inflammatory responses, including those mediated by angiotensin II and oxidative stress, result in extracellular matrix remodeling and fibrosis at various tissues, and that remodeling can be managed by PPARs, as shown in an experimental ischemic heart model and a streptozotocin-induced diabetic rat model with PPAR agonists (3). *In vivo* and *in vitro* studies with PPAR agonists showed that these agents can prevent inflammation in vessel walls, heart, kidney, adipose tissue, and human peritoneal mesothelial cells (4–6). Zhang *et al.* (7) described rat peritoneal mesothelial cell expression of PPARs and the potential role for these molecules in local peritoneal defense mechanisms by downregulation of inflammatory mediators. Recently, Yao *et al.* (8) showed that intraperitoneal rosiglitazone produces both morphology improvements and lower expression profiles of profibrotic mediators in peritoneum after exposure to conventional PD solutions.

We showed that renin–angiotensin system blockade (using angiotensin converting-enzyme inhibitors, angiotensin II receptor blockers, and combination treatment) and octreotide treatment improved peritoneal deterioration in the same chlorhexidine (CG)–induced EPS model in rats (9,10).

The aim of the present study was to investigate the effect of the PPAR agonist rosiglitazone on progression and regression of peritoneal alterations in CG-induced EPS in rats.

Materials and methods

We used 53 nonuremic female Wistar albino rats 8 weeks of age in the present study. All animal studies were performed according to National Research Council guidelines. Rats were housed in polycarbonate cages at 24°C room temperature with a 12-hour light–dark cycle, fed with a standard laboratory diet, and allowed free access to water. The Animal Ethics Committee of Ege University Hospital approved the study design.

To produce the experimental EPS model, we injected the rats intraperitoneally (IP) with 0.1% CG and 15% ethanol dissolved in saline as previously described (11). It has been reported that 3 weeks of CG injection IP is sufficient to induce marked neovascularization; mRNA expression of vascular endothelial growth factor, angiotensin I, and angiotensin II; and accumulation of $CD34^+$ cells in peritoneum (12). For that reason, we set a 3-week period of treatment with IP CG injection.

We divided the rats into 5 groups: control group (n = 10)—isotonic saline 2 mL, injected intraperitoneally (IP) daily for 3 weeks; CG group (n = 10)—CG 2 mL per 200 g body weight, injected IP daily for 3 weeks; Rozi-P (progression) group (n = 10)—CG injection as described, plus rosiglitazone [Avandia: GlaxoSmithKline, Stevenage, U.K.; 4-mg pills in drinking water (8 mg/L) for 3 weeks]; Resting group—CG injection as described during weeks 1 – 3, then peritoneal rest during weeks 4 – 6; Rozi-R (regression) group—CG injection as described during weeks 1 – 3, then rosiglitazone in drinking water (8 mg/L) during weeks 4 – 6. We calculated the amount of water consumed by each rat to determine that rat's rosiglitazone exposure. The daily dose of rosiglitazone was 0.1 mg/kg, equal to the dose per kilogram used by humans in managing insulin resistance.

A 1-hour peritoneal equilibration test (PET) with 25 mL 3.86% glucose PD solution (Dianeal: Eczacibasi–Baxter Healthcare, Istanbul, Turkey) was performed. After 1 hour, ketamine HCl anesthesia (60 mL/kg body weight) was applied, and blood samples were immediately collected by direct cardiac puncture. To avoid dialysate leakage, dialysate samples were obtained through a shortened dialysis catheter inserted into a midline incision.

Blood and dialysate urea were measured using an enzymatic kinetic method (Randox Laboratories, San Francisco, U.S.A.), and the dialysate-to-plasma ratio of urea (D/P urea) was calculated. The net UF was calculated as the difference between the instilled and the drained dialysate volumes. Dialysate cell count was taken as a white blood cell count (WBC) per cubic millimeter of dialysate.

In the histology examination, the anterior abdominal wall was fixed at room temperature in 4% buffered formalin solution instead of the usual 10% formalin (13); tissues were routinely processed and then embedded in paraffin. Sections 4 μm in thickness were stained with hematoxylin and eosin and with Masson trichrome for examination by light microscopy.

The slides were "blindly" examined by the same pathologist. The microscopic image was recorded at a typical area (200× magnification). Number and reactivity of mesothelial cells, presence of inflammation and mast cells, fibroblastic activity and fibrosis, vascularization, and peritoneal thickness were evaluated and semi-quantitatively scored. The semi-quantitative scores (0 – 3 points) for inflammation, fibroblastic activity, and neovascularization were obtained by counting mononuclear cells, fibroblasts, and capillaries at high-power magnification. Fibrosis was also scored based on evaluation of edema and collagen density. Number of mesothelial cells was evaluated as "decreased," "normal," or "increased." Mesothelial cells were classified as "normal" (flat cells) or "reactive" (cubic transformation of flat cells). Fibrosis was classified as "early" (edema and a few lacy collagens), "middle" (lacy and mature collagen), and "late" (mature collagen fibrils).

Parietal peritoneal surfaces were evaluated by morphometry. Thickening of the submesothelial zone was measured from the inner surface of the abdominal muscle to the mesothelium (peritoneal cavity) as reported in our previous studies (14). Submesothelial area, an area from the abdominal muscular surface to the peritoneal cavity, was also analyzed.

Images were analyzed with an Axiovision LE Imaging System (demo version 4.5: Carl Zeiss, Jena, Germany). At a minimum, a 450-μm length of parietal peritoneum and submesothelial zone was evaluated. The sectioned blood vessels within the compact zone were counted.

Results are reported as mean ± standard error of the mean (SEM). Statistical analyses were performed using analysis of variance, unpaired *t*-test, and the Mann–Whitney *U*-test. A *p* value of less than 0.05 was considered significant.

Results

Table I summarizes the results.

Functional changes

As seen in Table I, CG severely injured visceral peritoneal functions. As compared with the control group, the CG group showed a decreased capacity for UF and an increased D/P urea (–2.46 ± 0.94 mL vs. 7.81 ± 0.37 mL; 0.84 ± 0.02 vs. 0.44±0.02; both $p < 0.05$). Some beneficial effects were seen in the Resting group as compared with the CG group (higher UF and WBC count, both $p < 0.05$). In the Rozi-R (regression) group as compared with the Resting group, we observed significantly less neovascularization and peritoneal thickness. When we compared the Rozi-P (progression) group with the CG and Resting groups, rosiglitazone had no statistically significant beneficial effects on D/P urea (0.79 ± 0.02 vs. 0.84 ± 0.02 and 0.76 ± 0.02 respectively, both $p > 0.05$). However UF values were significantly better in the Rozi-P group than in the CG group (4.45 ± 1.05 mL vs. 2.46 ± 0.94 mL, $p < 0.05$).

Morphology changes

Figure 1 shows the morphology changes observed. No marked change was noted in the peritoneum of control rats. Effluent cell count, peritoneal thickness, number of vessels, and fibrosis score were worse in the CG group than in control rats (1006/mm^3 vs. 461/mm^3, 117 ± 10 μm vs. 8 ± 0.3 μm, 5.6 ± 0.8 vs. 0, and 1.4 ± 0.16 vs. 0.03 ± 0.03 respectively, all $p < 0.05$). As compared with 3 weeks of rosiglitazone treatment, peritoneal rest for 3 weeks had no beneficial effects on morphology changes induced by CG, except that the dialysate cell count was better than that seen in the CG group. In the Rozi-P group, rosiglitazone showed beneficial effects on the fibrosis score as compared with the scores in the Resting and Rozi-R groups (1.62 ±

0.26 vs. 1.8 ± 0.16, $p > 0.05$; and 1.62 ± 0.26 vs. 2.46 ± 0.18, $p < 0.05$).

Discussion

Pathologic changes in the peritoneal membrane with long-term PD are characterized by a decrease or loss of mesothelial cells, enlargement of the submesothelial compact zone as a result of interstitial fibrosis accompanied by degeneration of collagens, and vasculopathy. The peritoneal cavity is an active biologic compartment that normally contains mononuclear phagocytic cells, T and B lymphocytes, memory and effector T lymphocytes, natural killer cells, and immune active mesothelial cells. All of these cells, but especially mesothelial cells, can secrete almost all inflammatory cytokines, growth factors, and chemokines under physiologic or pathologic conditions (15–18). Various stimuli resulting from either bioincompatible PD fluids or peritonitis attacks cause inflammation in the peritoneum that finally ends with fibrosis (19). In addition to the many inflammatory cytokines and chemokines secreted, mesothelial cells also express a significant quantity of PPARs. Activation of these receptors has been shown to strongly inhibit lipopolysaccharide-induced inflammation in rat peritoneal mesothelial cells, implicating their potential role in peritoneal defense (7).

In the present study, 3 weeks of CG administration yielded EPS characterized by loss of UF, increased peritoneal thickness, inflammation, destruction of peritoneal membrane integrity, and ultimately, the development of fibrosis and encapsulation. Peritoneal rest provides some advantages, but only with regard to UF failure, D/P urea, and dialysate cell count. But the PPAR gamma agonist rosiglitazone was more effective than rest for almost all of the structural and functional parameters of peritoneum considered in the present study. With rosiglitazone, we observed improvements in all functional and morphologic parameters of the peritoneum exposed to CG. Although the present model is more suitable for an examination of morphologic parameters than of functional parameters, we noted an improvement in D/P urea and UF capacity with rosiglitazone. The decreased inflammatory cell count and neoangiogenesis shown in Figure 1(D,E) might ultimately lead to less thickness and increased UF capacity.

Use of PPAR gamma agonists to regulate TGF/Smad pathways in peritoneum after exposure to PD solutions had been shown to inhibit well-known fibrotic pathways (8). We can speculate that TGF/Smad pathways may play a role in the beneficial results seen in the present study.

Agonists of PPARs have been successfully used in various inflammatory conditions, including as an insulin sensitizer, an anti-atherosclerotic and anti-inflammatory agent in metabolic syndrome (4), and an antiproliferative agent in stent restenosis (20). The increased UF capacity with decreasing peritoneal thickness, cellularity, and vascularity under rosiglitazone administration that we observed in the present experiments may be the result of anti-proliferative and anti-inflammatory effects on mesothelial cells via PPAR gamma receptors, which are expressed in mesothelial

TABLE I Histologic results of the experiments

Characteristic	*Control* (n=*10*)	*CG* (n=*10*)	*Resting* (n=*10*)	*Rozi-R* (n=*13*)	*Rozi-P* (n=*10*)
Ultrafiltration (mL)	7.81±0.37	–2.46±0.94[a]	2.86±0.54[a,b]	3.46±0.36[a,b]	4.45±1.05[b]
D/P urea	0.44±0.02	0.84±0.02[a]	0.76±0.02[a]	0.45±0.02[b,c]	0.79±0.02[d]
WBCs (mm^3)	461	1006[a]	593[b]	476[b]	661[b]
Peritoneal thickness (μm)	8±0.3	117±10[a]	129±14	89±10[b,c]	93±7
Inflammation	0	1.1±0.1[a]	1.16±0.16	0.92±0.13	1.1±0.2
Vessels (*n*)	0	5.6±0.8[a]	12±3[b]	3.69±0.73[c]	3.88±0.9
Fibroblasts	0.03±0.03	1.4±0.16a	1.8±0.16b	2.46±0.18[b,c]	1.62±0.26[d]

[a] $p < 0.05$ vs. Control.
[b] $p < 0.05$ vs. CG.
[c] $p < 0.05$ vs. Resting.
[d] $p < 0.05$ vs. Rozi-R.
CG = chlorhexidine group; Resting = peritoneal rest group; Rozi-R = rosiglitazone regression group; Rozi-P = rosiglitazone progression group; D/P = dialysate-to-plasma ratio; WBCs = white blood cells.

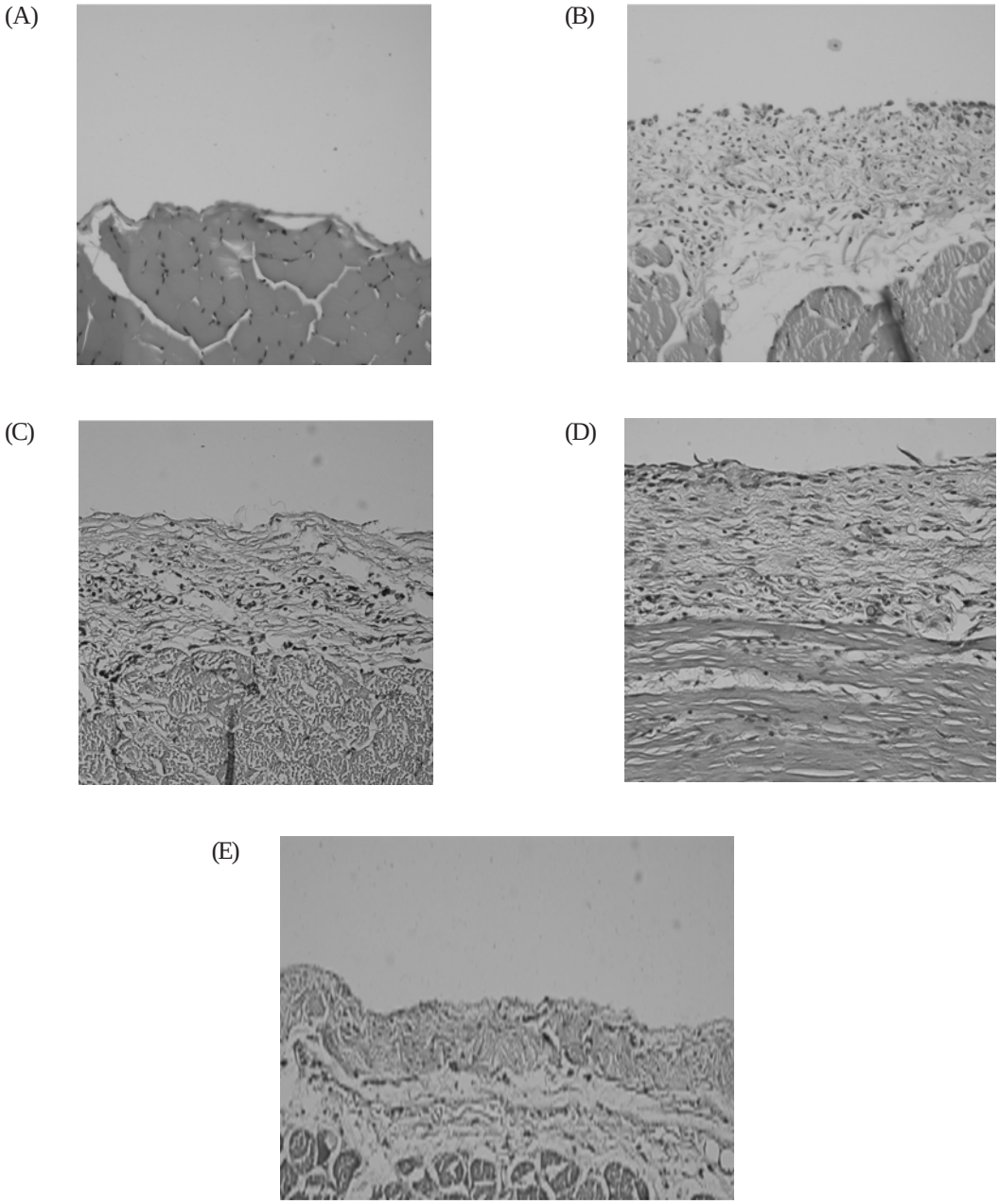

FIGURE 1 Histologic features of the parietal peritoneum (hematoxylin–eosin, 200× magnification). (A) An intact thin peritoneal mesothelial layer overlies the muscle in the control group. (B) Chlorhexidine significantly increased thickness, cellularity (inflammation), and fibrotic changes. (C) Peritoneal rest had no morphologic benefits; vascularity, thickness, and fibrosis still increased in the Resting group. (D) The rosiglitazone progression group is characterized by decreased cellularity (inflammation) and thickness, with a smaller number of visible vessels as compared with the Resting group. (E) The rosiglitazone regression group shows fibrosis with mild cellularity (inflammation) and vascularity.

cells in various inflammatory conditions. Also, rosiglitazone may possibly inhibit epithelial-to-mesenchymal transition in mesothelial cells; however, the molecular pathways affected by rosiglitazone in that instance must be clarified.

As shown by other therapeutic approaches to the management of EPS (with somatostatin, colchicine, and tamoxifen, for instance), resting phenomena may have no benefit for EPS. If the peritoneum stimulated into fibrosis is considered an irreversible process, then implementing some preventive measures in the early period of EPS would be meaningful. Notably, inflammation, thickness, and vascularity continued to increase during peritoneal rest, indicating that peritoneum was still active in that period.

Kawanishi *et al.* (21) reported that, after cessation of PD for even up to 4 years, a continuing risk for the development of EPS remained. Significant numbers of patients have developed EPS an average of 4 months (and as long as 4 years) after withdrawal from PD therapy. In the present study, peritoneal rest had benefits only on dialysate cell count and UF capacity as compared with those parameters in the CG group, but not in the Rozi-R group. Scores for peritoneal thickness, vascularity, and fibrosis continued to increase during the additional 3 weeks of rest after CG exposure. Our experimental results accord with the clinical results from the study by Kawanishi *et al.*

Considering that EPS has no established therapy and that preventive measures are important, our findings from the additional 3 weeks of rosiglitazone therapy—including decreased vascularity, peritoneal thickness, and cellularity—are promising as preventive measures. As compared with the CG group, the Rozi-P group showed insignificant beneficial effects from rosiglitazone. The fibrosis score was less in the Rozi-P group than in the CG and the Rozi-R groups. That finding supports the potential preventive role of rosiglitazone on peritoneal derangements in patients either because of bioincompatible PD solutions or longevity of PD therapy. Recently, antifibrotic therapies have become more popular in fibrotic diseases such as pancreatic fibrosis (22) and liver fibrosis (23). In the same manner, given the findings regarding the fibrosis score in the Rozi-P group in our study, PPAR agonists may have a role in the antifibrotic milieu, helping in the management of EPS. However, this issue must be clarified in clinical studies.

Given the growing numbers of diabetic patients with end-stage renal disease (ESRD) throughout the world, the use of PPAR agonists in diabetic patients on CAPD will have some additional advantages beyond membrane protection: they may help with cardiovascular burden. It is also important to note the side effects of this class of agents on salt and water retention in such high-risk patients; however, because of the loss of tubular functions in patients with ESRD, these side effects are unlikely to result in hypervolemia in this population.

Conclusions

Rosiglitazone, a PPAR gamma agonist, improved all of the structural and functional parameters of peritoneum in an experimental EPS model. The preventive and therapeutic potency of rosiglitazone as shown in the progression and regression models respectively must be taken into consideration for patients having an increased risk for the rare but highly fatal condition of EPS.

We believe that future comparisons of rosiglitazone with other therapeutic agents such as corticosteroids, tamoxifen, and azathiopurine will clarify the exact role of this agent in the treatment of EPS.

Acknowledgments

The authors thank Figen Çetin for his technical assistance and Dr. Dimitrios G. Oreopoulos for reviewing the manuscript.

References

1 Chew MH, Sophian Hadi I, Chan G, Ong HS, Wong WK. A problem encapsulated: the rare peritoneal encapsulation syndrome. Singapore Med J 2006;47:808–10.
2 Pusateri R, Ross R, Marshall R, Meredith JH, Hamilton RW. Sclerosing encapsulating peritonitis: report of a case with small bowel obstruction managed by long-term home parenteral hyperalimentation, and a review of the literature. Am J Kidney Dis 1986;8:56–60.
3 Toba H, Miki S, Shimizu T, *et al.* The direct antioxidative and anti-inflammatory effects of peroxisome proliferator–activated receptors ligands are associated with the inhibition of angiotensin converting enzyme expression in streptozotocin-induced diabetic rat aorta. Eur J Pharmacol 2006;549:124–32.
4 Staels B. PPAR agonists and the metabolic syndrome. Therapie 2007;62:319–26.

5 Liu H, Peng YM, Liu FY, *et al.* Inhibitive effect of troglitazone on TGF-beta(1) and fibronectin expression in human peritoneal mesothelial cells (Chinese). Zhong Nan Da Xue Xue Bao Yi Xue Ban 2007;32:473–9.
6 Peng Y, Liu H, Liu F, Liu Y, Li J, Chen X. Troglitazone inhibits synthesis of transforming growth factor-β1 and reduces matrix production in human peritoneal mesothelial cells. Nephrology (Carlton) 2006;11:516–23.
7 Zhang YF, Yang X, Zhang YJ, *et al.* Peroxisome proliferator–activated receptor-γ is expressed by rat peritoneal mesothelial cells: its potential role in peritoneal cavity local defense. Am J Nephrol 2006;26:602–11.
8 Yao Q, Pawlaczyk K, Ayala ER, *et al.* Peroxisome proliferator-activated receptor-γ agonists diminish peritoneal functional and morphological changes induced by bioincompatible peritoneal dialysis solution. Blood Purif 2006;24:575–82.
9 Sipahi S, Bozkurt D, Sezak M, *et al.* Does renin angiotensin system blockage preserve morphological and functional changes in encapsulated peritoneal sclerosis? In: Book of Abstracts of the 8th European Peritoneal Dialysis Meeting; July 7 – 10, 2007; Helsinki, Finland. Edinburgh, U.K.: EuroPD; 43. [Available online at: www.europd.com/downloads/poster-abstracts.pdf]
10 Sipahi S, Bozkurt D, Sezak M, *et al.* Octreotide ameliorates and regresses morphological changes in encapsulated peritoneal sclerosis (Abstract 145). In: Book of Abstracts of The 8th European Peritoneal Dialysis Meeting; July 7 – 10, 2007; Helsinki, Finland. Edinburgh, U.K.: EuroPD; 43. [Available online at: www.europd.com/downloads/poster-abstracts.pdf]
11 Hoff CM. Experimental animal models of encapsulating peritoneal sclerosis. Perit Dial Int 2005;25 (Suppl 4):S57–66.
12 Io H, Hamada C, Ro Y, Ito Y, Hirahara I, Tomino Y. Morphologic changes of peritoneum and expression of VEGF in encapsulated peritoneal sclerosis rat models. Kidney Int 2004;65:1927–36.
13 Sen S, Duman S, Basçi A, Akçiçek F, Atabay G. Parietal peritoneal morphology with different fixatives in experimental studies (Abstract). Perit Dial Int 2002;22(Suppl 1):S152.
14 Duman S, Sen S, Günal AI, Asci G, Akçiçek F, Basçi A. How can we standardize peritoneal thickness measurements in experimental studies in rats? Perit Dial Int 2001; 21(Suppl 3):S338–41.
15 Tellado JM, Broche F. Defense mechanisms of the peritoneal cavity. Curr Opin Crit Care 2001;7:105–16.
16 Kubicka U, Olszewski WL, Tarnowski W, Bielecki K, Ziólkowska A, Wierzbicki Z. Normal human immune peritoneal cells: subpopulations and functional characteristics. Scand J Immunol 1996;44:157–63.
17 Jayne DG, Perry SL, Morrison E, Farmery SM, Guillou PJ. Activated mesothelial cells produce heparin-binding growth factors: implications for tumour metastases. Cancer 2000;82:1233–8.
18 Hausmann MJ, Rogachev B, Weiler M, Chaimovitz C, Douvdevani A. Accessory role of human peritoneal mesothelial cells in antigen presentation and T-cell growth. Kidney Int 2000;57:476–86.
19 Hekking LH, Harvey VS, Havenith CE, *et al.* Mesothelial cell transplantation in models of acute inflammation and chronic peritoneal dialysis. Perit Dial Int 2003;23:323–30.
20 Joner M, Farb A, Cheng Q, *et al.* Pioglitazone inhibits in-stent restenosis in atherosclerotic rabbits by targeting transforming growth factor-beta and MCP-1. Arterioscler Thromb Vasc Biol 2007;27:182–9.
21 Kawanishi H, Kawaguchi Y, Fukui H, *et al.* Encapsulating peritoneal sclerosis in Japan: a prospective, controlled, multicenter study. Am J Kidney Dis 2004;44:729–37.
22 Jaster R, Lichte P, Fitzner B, *et al.* Peroxisome proliferator-activated receptor gamma overexpression inhibits pro-fibrogenic activities of immortalised rat pancreatic stellate cells. J Cell Mol Med 2005;9:670–82.
23 Xu J, Fu Y, Chen A. Activation of peroxisome proliferator-activated receptor-gamma contributes to the inhibitory effects of curcumin on rat hepatic stellate cell growth. Am J Physiol Gastrointest Liver Physiol 2003;285:G20–30.

Corresponding author:
Soner Duman, MD, Ege Üniversitesi Tip Fakültesi, Nefroloji Bilim Dali, Bornova, Izmir 35100 Turkey.
E-mail:
soner.duman@ege.edu.tr, sonerduman@hotmail.com